

Unusual Metastasis of Thyroid Carcinomas: A Series of 485 Patients

Soumeya Fedala¹, Haddam Ali El Mahdi,¹ Ahmed Ali Leyla², Kabour Saidia³

Department Of Endocrinology, Bab El Oued Hospital, Algiers

1Department Of Diabetology, Bab El Oued Hospital, Algiers

Abstract: Differential carcinoma is the most common cancer of the thyroid. Usually of good prognosis, it is characterized by mostly locoregional locations¹. Remote metastasis are mainly lung and bone. The other locations are much rarer (brain, mediastinum, skin, liver, eye, adrenal ...). In our study, they were found in 1.85% of cases. Predominant in the female sex (67%), they are more common in vesicular carcinomas (77%) than in pure papillary carcinomas (22%) ($p = 0001$). The average age of diagnosis of metastasis is 53 ± 4.2 years with an average of 3 ± 0.5 years after the diagnosis of thyroid carcinoma (50 ± 2.3 years). The frequency of unusual metastasis were in order hepatic (55%), adrenal (44%), choroidal (22%) cerebellar (22%), renal (11%) and skin (11%). They are radioactive iodine fixating in 22% of cases. 55% of the patients had advanced carcinoma at diagnosis (stage IV). The evolution was complicated by mortality in 22% (half of them had adrenal metastases) and morbidity in 78% of cases. mean survival was 3 ± 1.5 years

Keywords: Unusual metastases ; vesicular carcinomas; radioactive iodine

I. Introduction

Differential carcinoma is the most common cancer of the thyroid. Usually of good prognosis, it is characterized by mostly locoregional locations.¹ Remote metastases are mainly lung and bone. The other locations are much rarer (brain, mediastinum, skin, liver, eye, adrenal ...) .They were observed in 10% of cases,² and are usually associated with bone and lung metastases.² Their occurrence significantly worsens the prognosis and is the leading cause of death The aim of our study was to report Unusual métastases of differentiated thyroid cancer specifying their clinical and progressive particularities

Population and Methodology

This is a retrospective study of 485 patients with differentiated thyroid carcinoma and monitored endocrinology between 1988 and 2013. We searched for patients the existence of unusual metastasis, clinical and evolutionary characteristics of the primary neoplasm

II. Results

The unusual metastases are rare (1.85%). They are less frequent than classically lung and bone metastases described (14%) ($p = 0.05$). Predominant in the female sex (67%), they are more common in vesicular carcinomas little or well differentiated (77%) than in pure papillary carcinomas (22%) ($p = 0001$) (fig1) . The average age of diagnosis of these metastases is 53 ± 4.2 years with an average of 3 ± 0.5 years after the diagnosis of thyroid carcinoma (50 ± 2.3 years).

The diagnosis of metastases was made as part of staging in 89%. In one case, metastasis was indicative of thyroid carcinoma. these unusual metastases were symptomatic in 55% of cases and diagnosed in poly metastatic context in 67% of cases. They were associated to classical metastases (lymph nodes, bone and lung) in 35% of cases.

The unusual metastases were in order of frequency of hepatic (55%), adrenal (44%), choroidal(22%) cerebellar (22%), renal(11%) and skin (11%)(fig2) They are fixating radioactive iodine in 22% of cases .The half of patients (55%) had advanced cancer at diagnosis: stage IV :55% .Stage III : 40% , stage II: 5%(fig3)

The evolution was complicated by mortality observed in 22%(half of them had adrenal metastases) and morbidity in 78% of cases. mean survival was 3 ± 1.5 years

III. Discussion

Unusual metastases of thyroid carcinomas are very rare. Few cases have been reported in the literatures. Indeed, the thyroid carcinoma metastasized generally in the lung and the bones^{3,4} rarely in the brain, liver and skin.⁵ The distant metastasis of these sites, especially choroidal are actually exceptional.⁶ These metastases are more frequently observed in women occur in patients around fifty. Primitive thyroid neoplasia is often diagnosed at an advanced stage(than 4cm and causing a break-capsular ,stage IV) in anatomy pathology The discovery of these lesions may raise the problem of a combination with another cancer . nIn fact

histological analysis of metastasis can be difficult. Markings in immunohistochemistry are then very useful.

The positivity of immuno marking for the thyroglobulin antibodies permits to certify the primitive thyroid cancer and to consider specific treatments.

Their presence at the time of initial diagnosis or during évolution is an extremely unfavorable factor that must be considered when the patient's care. Indeed, frequent association with other distant metastases darkens the prognosis of these patients who the duration of survival is about one year. A strong correlation between the occurrence of these metastases and the presence of metastatic bone especially broadcast and pulmonary is generally recognized. Appeared heavily compromise the functional and vital prognosis of patients. Unusual metastases of thyroid carcinomas are rising sharply. Many of them remain asymptomatic.

The patients die of their primary cancer or other complications before their clinical expression. Therefore their frequency is certainly underestimated. The most frequently identified locations in the literature are the hepatic and adrenal metastasis. Their spontaneously very poor prognosis, require systematically looking for in case of poly metastatic locations.

Support unusual metastasis involves a multidisciplinary approach. Indeed, if the radiation treatment by ¹³¹I remains a reference method for the management of metastatic differentiated thyroid carcinomas , unusual metastasi s do not fix iodine. Surgery with radiotherapy or chemotherapy when the mass is not fully extirpable are then the only alternative.

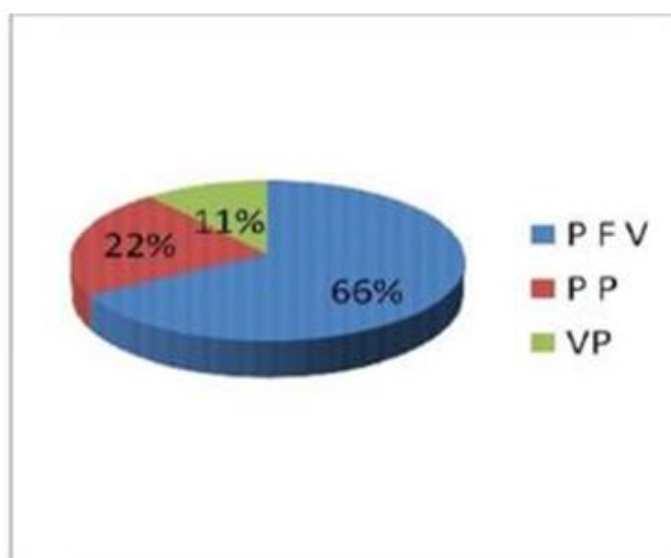
New targeted therapies have their place in the management of unusual metastasis. They should be considered when the tumor lesions are scalable despite the treatments mentioned above. The difficulty of availability and high cost, however, limits their use in our country

IV. Conclusion

Unusual metastases of thyroid cancers are rare. They are more frequent in thyroid follicular cancers poorly differentiated and context of poly metastatic locations include pulmonary and bone. They should be discussed and treated early because they occurred darkens the functional and vital prognostic

References

- [1]. Troutoux J., Aidan D. -Tumors The Thyroid . Emc, Orl, 20-875-A-10, 1997, 12p.
- [2]. Shaha Ar, Ferlito A, Rinaldo A. Distant Metastases From Thyroid And Parathyroid Cancer. Orl J Otorhinolaryngeal Relat Spec. 2001;63:243- 249.
- [3]. Ahmadi M.A., Nicholes D., Esmaeli B. Late Choroidal Metastasis Secondary To Papillary Thyroid Carcinoma. Am J Ophthalmol 2001;132:796-8.
- [4]. Dahl Pr, Brodland Dg, Goellner Jr, Hay Id. Thyroid Carcinoma Metastatic To The Skin: A Cutaneous Manifestation Of A Widely Disseminated Malignancy. Jam Acad Dermatol. 1997;36:531-7.
- [5]. Ferry A.P, Font R. -Dcarcinoma Metastatic To The Eye And Orbit. I.A Clinicopathologic Study Of 227 Cases. Arch Ophthalmol., 1974; 92: 276-286.
- [6]. Ferry Garcia J.C., Merino Tores J.F., Ponce Marco J.L., Pinon Selles F. Unusual Metastasis Of Differentiated Thyroid Carcinoma. An Med Internat 2002; 19, 579-



Figures

Figure 1: Type of tvroid carcinoma(PP pure papillary. VP : pure vesicular. PF follicular papillary

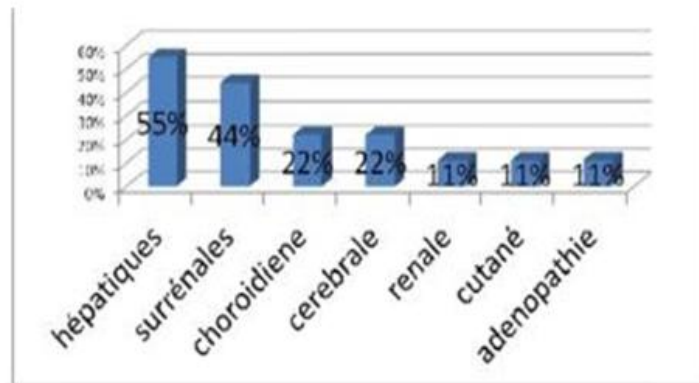


Fig2: the unusual metastases in thyroid carcinoma

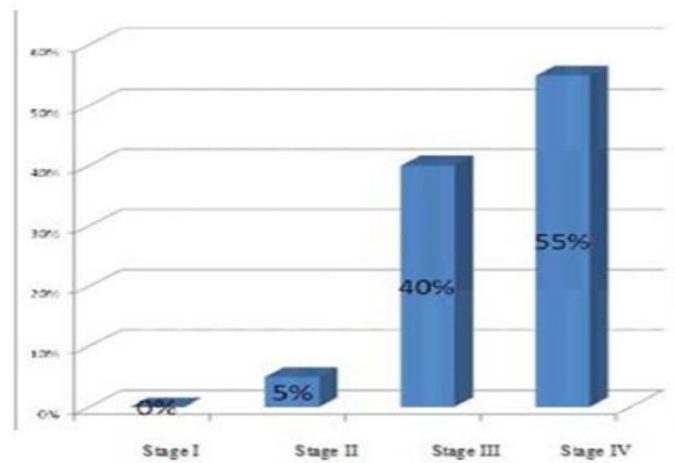


Fig 3: Staging of thyroid carcinoma